



PATIENT

Samson Zabriskie

SPECIES

Canine

BREED

Pomeranian

SEX

Male Neutered

AGE

8 years

WEIGHT

12.2lbs

PRESENTING CLINICAL SIGNS

History: Presenting for chronic cough and slightly enlarged VHS 11. No murmur. New elevation of ALT 143, ALP 183. Dog is clinically normal otherwise. *Having bi-cavity ultrasound exams.

ECHOCARDIOGRAM FINDINGS

2D, m-mode, color flow and Doppler imaging is available.

Left ventricle: The LV diameter is normal with adequate myocardial function. LV wall thicknesses are normal.

Left atrium: The left atrium normal.

Mitral valve: The mitral valve is mildly thickened with no prolapse into the left atrial lumen. Trace central mitral regurgitation.

Aortic valve/aorta: The aortic valve is normal in morphology and mobility. Normal aortic outflow velocity; laminar flow. No aortic insufficiency.

Right ventricle: Normal right ventricular diameter and morphology indicating no overt evidence of pulmonary arterial hypertension.

Right atrium: Normal RA dimension.

Tricuspid valve: The tricuspid valve appears normal with trace tricuspid regurgitation. Normal velocity.

Pulmonic valve/pulmonary artery: The pulmonic valve is normal in morphology and mobility. No pulmonic insufficiency. Normal RVOT velocity; laminar flow.

Pericardium/other: No pericardial or pleural effusion noted. No obvious cardiac masses.

Heart rhythm: ECG reveals a sinus rhythm with an average HR of 90bpm.

INTERPRETED BY

Maggie Machen
Lamy, DVM
DACVIM (Cardiology)

2-Dimensional Measurements

Ao diam (cm)	1.4
LA diam (cm)	1.7
LA:Ao (Swe)	1.3
IVS thickness (cm)	0.7
LVID diastole (cm)	2.3
PW thickness (cm)	0.7
LVID systole (cm)	1.3
FS (%)	45

Doppler Measurements

PV Vmax (m/s)	0.65
AoV Vmax (m/s)	1.3
MR Vmax (m/s)	NA
TR Vmax (m/s)	2.5
TR PG (mmHg)	25

IMAGING

PERFORMED BY

Pamela Harrigan,
RDCS

INTERPRETATION OF THE FINDINGS

Overtly normal cardiac dimensions and function, with no obvious dysfunction or dilation of the left heart. Trace MR and TR may reflect early valve disease and follow up is advised should a murmur be ausculted in the future. No other significant valvular leaks are visualized, and no evidence of pulmonary hypertension. No additional issues are identified.

HOSPITAL NAME

Wood River Animal
Hospital

REFERRING VET

Dr. Schuelke

INVOICE

29567

DATE

3/31/23

No cardiac medications are indicated at this time as the cough appears non-cardiac in origin. Continued work up for infectious/inflammatory respiratory causes is recommended if the cough persists/recurs. Chronic respiratory signs can lead to pulmonary hypertension if poorly controlled and monitoring at home is advised for exertional syncope or dyspnea.



PATIENT

Samson Zabriskie

SPECIES

Canine

BREED

Pomeranian

SEX

Male Neutered

AGE

8 years

WEIGHT

12.2lbs

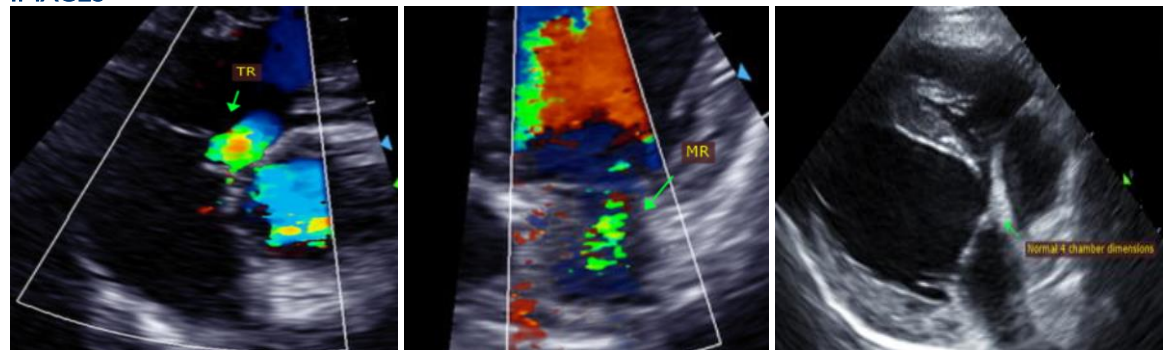
RECOMMENDATIONS

- No cardiac medications are clearly indicated.
- Omega fatty acid supplementation and mild salt restriction may be of some long-term benefit.
- Monitor for development of a murmur, cough, labored breathing, exercise intolerance or collapse episodes.

PLAN

- A recheck echocardiogram is recommended should a murmur or signs of progressive PAH be noted in the future.

IMAGES



INTERPRETED BY

Maggie Machen
 Lamy, DVM
 DACVIM (Cardiology)

The information and recommendations provided are based on the images presented by the referring veterinarian. No evaluation can be communicated regarding pathology that was not visible in the image/video clips provided.

Thank you for this referral. This report was generated using transcription software, and minor dictation errors may be present. If the clinical or image interpretation does not parallel your findings or if I can be of any further assistance, please contact me.

IMAGING PERFORMED BY

Pamela Harrigan,
 RDCS

Maggie Machen Lamy, DVM
 Diplomate of the American College of Veterinary Internal Medicine (Cardiology)
 info@sonopath.com

HOSPITAL NAME

Wood River Animal
 Hospital

Echocardiogram performed by: Pamela Harrigan, RDCS
 Pet Animal Ultrasound Service (4paus.com)

REFERRING VET

Dr. Schuelke

INVOICE

29567

DATE

3/31/23